

Subcision for treatment of rolling acne scars in Iraqi patients: a clinical study

Muhsin A AL-Dhalimi, MD¹ & Ahmad A Arnoos, FICDV²

¹Department of Dermatology, College of Medicine, University of Kufa, Kufa, Iraq

²Alsadir teaching Hospital, Najaf Health Directorate, Najaf, Iraq

Summary

Background Acne scarring is a common dermatologic problem causing a great cosmetic disfigurement. Subcision is one of the effective modalities for treatment of rolling acne scars.

Objective To evaluate the efficacy and safety of subcision for rolling acne scars in Iraqi patients.

Patients and Methods Forty patients (21 males and 19 females) with moderate to severe grades of facial rolling acne scars were enrolled in this study. Subcision was done for all patients. Patients were followed up at 2, 6, 12 weeks, and 6 months after the last session. The response to treatment was evaluated by objective and subjective methods.

Results Thirty-four patients completed the study and follow up period. Eight of them were complaining of severe and 26 of moderate grade of acne scars. At the end of the study, 18 (52.94%) patients had mild grade, 15 (44.11%) patients had moderate grade, and one (2.92%) patient had severe grade. This change was statistically highly significant (P -value = 0.0000001). The average scar score before treatment was 13.264 ± 1.675 ; and it improved to 9.47 ± 2.71 after 6 months (P -value = 0.0000001). Regarding the photographic assessment, the difference in the visual analogue scale before and after the treatment was statistically highly significant (P -value = 0.0000001). All patients were satisfied regarding the improvement after treatment with varying degrees. All reported side-effects were mild and transient.

Conclusion Subcision is a safe, easy to perform, well-tolerated, and valuable surgical technique for treatment of rolling acne scars.

Keywords: acne scars, Iraqi patients, subcision

Introduction

Acne is a prevalent condition and often results in secondary damage in the form of scarring.¹ Scarring usually follows deep inflammatory lesions, but may often happen after superficial lesions in scar-prone patients. Close inspection of acne skin under a bright light can

reveal some scarring in up to 90% of the patients who attend dermatology clinics, but significant (socially noticeable) scarring found in about 22% of them.² Unfortunately, it is a permanent complication and has serious impacts on the psychology of the individual as it will accompany him for the rest of life. Acne scars can exist in many forms, such as superficial macular, icepick, rolling, boxcar, hypertrophic scars, and keloids.³ Rolling acne scars characterized by gently undulating broad base with steep edges. It lacks the sharp edge and crater of icepick and boxcar types.

Correspondence: M A AL-Dhalimi, MD, PO Box 591, Najaf post office, Najaf, Iraq. E-mail: muhsinaa@med.kuiraq.com

Accepted for publication February 5, 2012

Table 1 Sharquie's scoring system for grading scarring acne vulgaris

Parameter	Score				
	1	2	3	4	
1	No. of scars	≤10	11–20	21–30	>30
2	Area involved	≤¼	>¼–½	>½–¾	>¾
3	Type of scars	Flat	Depressed	Hypertrophic	Keloid
4	Colour of scars	Skin colored	Erythematous or hypopigmented	Hyperpigmented	Bluish or grayish
5	Effect on psyche	No effect or mild discomfort	Mild dysmorphophobia	Moderate dysmorphophobia	Severe dysmorphophobia or social withdrawal

Recently, Sharquie *et al.*⁴ published a scoring system for grading of the acne scars consisting of five parameters (Table 1). This system scores from 5 to 20 points. Grading of acne scars is as follows: mild (5–9), moderate (10–14), and severe (15–20).

Treatment of the acne scars must reflect several considerations by the physician. Cost of treatment, type, and severity of lesions, physician goals, patient expectations, side-effect profiles, psychological or emotional effects on the patient, and prevention measures are all important.^{1,5,6} Treatment modalities include medical treatment (retinoids, topical and injectable steroid, silicone dressing ...etc.),¹ surgical treatment (punch excision, elliptical excision,⁷ punch elevation, and debulking),¹ procedural treatment (cryosurgery, electro-dessication, radiation, chemical peels, microdermabrasion, and dermabrasion),^{1,8–10} Tissue augmentation,¹ Light (IPL),¹¹ laser (CO₂ laser, Er: YAG laser)^{12,13} and energy therapy (plasma and radiofrequency).^{14,15} None of these is suitable for all patients and combination of approaches may be needed according to the type and severity. This approach can give results superior to those possible with just one technique.¹⁶

Subsision is defined as a method for subdermal undermining of the depressed areas or it is undermining of scars, wrinkles or cutaneous depressions by breaking up the attachments of these contour abnormalities and releasing the surface from deeper structures. Since 1995, subsision was established as effective means of correcting rolling depressed acne scar and wrinkles. Orentreich and Orentreich,¹⁷ who first described the procedure, called it subsision to stand for *subcutaneous incisionless* surgery for correction of depressed scars and wrinkles. It has been used for treatment of acne scars on limited bases.^{16–20} Subsision have been tried also to treat striae and cellulite.^{21,22} The aim of the current study was to evaluate the effectiveness and safety of subsision in Iraqi patients with rolling acne scars.

Patients and methods

This open label therapeutic study was carried out in the department of Dermatology and Venereology, Al-Sadir teaching hospital in Najaf during February 2008 to October 2009.

The inclusion criteria were patients with bilateral facial, predominantly depressed rolling, acne scars with any grade of severity (mild, moderate, and severe). We follow Sharquie's scoring system for grading scarring acne vulgaris.⁴ The exclusion criteria were: patients with icepick scars only, those with active acne under the scar or active infection and those with history of keloid scarring after trauma or surgery. Also, patients with bleeding diathesis, anticoagulant medication, antiepileptic drugs, diabetes mellitus, ischemic heart disease, pregnant women, and those who are unable to take care of their wounds were excluded. All patients were evaluated by the history and physical examination. A full history was taken with emphasis on age, sex, duration of the scar, effect on psyche, activity of the disease, medications, drug allergy (especially lidocaine, adrenaline and antibiotics), bleeding tendency, ischemic heart disease and history of keloid formation after trauma or surgery. A careful physical examination was carried out to identify the presence of active acne lesions, site, type, area and color of acne scars. Previous scars in other sites were examined for normal healing, hypertrophy or keloid formation. Patients were instructed to avoid aspirin and other medications that affect blood clotting. The female patients were informed not to put makeup on the day of the operation. A written consent was taken from all patients before the procedure. This study was approved by the local ethical committee.

The procedure started by cleaning of the treated areas to remove dirt. Overhead lighting is adjusted to fully and precisely delineate the depressions on the face which

then out-lined with a fine tip water resistant surgical marking pen by placing dots on depressed scars. Local infiltration of 1% lidocaine with 1:100 000 epinephrine into the superficial subcutis is used in all patients. It was enough to allow insertion of the needle about 1 Cm from the treated scar.

An 18G needle was used for subsicion of all scars (Fig. 1). The needle was held by a needle holder for better orientation of the sharp tip of the needle and to keep it horizontal to the skin surface without withdrawing it from the entry point. The triangular tip of the needle was inserted in a horizontal orientation (i.e. parallel to the skin surface) to the mid or deep dermis with the sharp end facing upward to cut the fibrotic bands at that level and to avoid injuring deeper structures. The needle was slowly advanced parallel to the dermis. Rapid, repetitive advancement, and retraction movements of the needle under the scarred area were done to abrade the underside of the dermis and cut any fibrous adhesions to the underlying structure. This action was repeated in a fan like pattern until complete release the entire lesion. Larger scars were treated through two or three entry sites to achieve a thorough soft tissue release. A topical antibiotic (Fucidine cream 1%, sammara drug industry) was applied to all patients after subsicion for 3 days to prevent wound infection. Subsequent sessions, if needed, were done with 6 weeks apart.

The patients were seen regularly 2, 6, 12 weeks, and 6 months after the last session. At each visit, the response to the treatment was assessed, the side-effects were recorded, photographs were taken, and Sharquie's scoring was evaluated. A visual analogue scale (VAS) from 0 to 10 was made to assess the severity of acne scars for each patient by a computer view of their photographs before and 6 months after the treatment

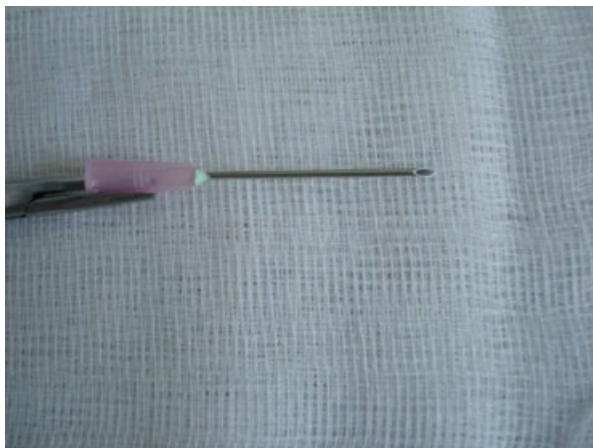


Figure 1 An 18 G needle held by a needle holder.

sessions. The evaluation was done by two independent board qualified dermatologists who were not member of the research team. At the 6 months visit the patient satisfaction was assessed. The patient's were divided into four grades according to their satisfaction with the procedure as follows: grade 0 (not satisfied), grade 1 (moderately or partially satisfied), grade 2 (greatly but not fully satisfied), and grade 3 (fully or completely satisfied). Statistical analyses were done through descriptive and analytical statistics using scientific calculator and EPI-info version 6 considering *P*-value of ≤ 0.05 as significant.

Results

Forty patients were included in this study. The age range was 17–36 years with a mean \pm SD of 23.475 ± 4.494 years. The duration of acne varied between 2–15 years with a mean \pm SD of 3.962 ± 3.575 years. There were 21 (52.5%) male patients and 19 (47.5%) female patients. According to Sharquie scoring system for grading scarring acne, 27 patients had moderate grade (10–14 score) and 13 patients had severe grade (15–20 score). The main scar type in all patients was rolling scars with minority of icepick scars.

All patients were treated with subsicion. Six patients were declined from the study after first treatment session for unknown reasons without any immediate -complication. Thirty-four patients completed the study. Sixteen (47.05%) patients were men and 18 (52.9%) were women. The number of sessions for each patient ranged from 1 to 3 sessions with a mean \pm SD of 1.2 ± 0.516 sessions. The number of sessions needed by the patient was decided by the treating physicians. The total number of sessions for the patients who completed the study was 42 sessions. Twenty-eight (82.35%) patients needed only one session, four (11.76%) patients needed two sessions and two (5.88%) patients needed three sessions. The number of sessions needed by each patient depended on the cosmetic satisfaction of the patient and to treat nontreated or partially-treated lesions.

Evaluation

The response of acne scars to subsicion was evaluated objectively and subjectively by the following methods:

Objective methods

Sharquie's scoring system for grading scarring acne vulgaris Eight (23.52%) of the 34 patients who completed the study were complaining of severe grade; after 2 weeks,

three patients (37.5%) improved to moderate grade; after 6 weeks, 7 (87.5%) of them progressed to moderate grade; after 12 weeks, 2 (25%) of them became of mild grade and five (62.5%) of moderate grade; and after 6 months, no further change was noticed. One of (12.5%) the eight severe grade patients remained in the same grade after two sessions.

Twenty-six (76.48%) patients were complaining of moderate grade before treatment. After 2 weeks of treatment, only one (3.84%) of them improved to mild grade; after 6 weeks, 13 (50%) patients had mild grade; after 12 weeks, 16 (61.53%) patients became of mild grade; and after 6 months, no further change in the improvement.

Overall, we had no patient with mild grade, 26 (76.48%) patients with moderate grade, and 8 (23.52%) patients with severe grade. After 2 weeks of treatment, we had one (2.92%) patient with mild grade, 28 (82.35%) patients with moderate grade, and 5 (14.7%) patients with severe grade. At 6 weeks after treatment, there were 13 (38.23%) patients with mild grade, 20 (58.82%) patients with moderate grade, and one (2.92%) patient with severe grade; whereas at 12 weeks and 6 months after treatment, we had 18 (52.94%) patients with mild grade, 15 (44.11%) patients with moderate grade and one (2.92%) patient with severe grade (Table 2). The difference in the grades was statistically significant ($P = 0.0000001$). The change in the average score of the 34 patients was shown in (Table 3). The decrease in the score was statistically significant ($P = 0.0000001$) using ANOVA test.

Photographic evaluation The mean score value of the VAS before treatment was 5.828 ± 1.807 , whereas the mean score value after treatment was 3.088 ± 1.725 (Table 4). The difference in the VAS before and after

6 months of the treatment using paired *T*-test was statistically highly significant (P -value = 0.0000001) (Figs 2 and 3).

Subjective method

Patients satisfaction was recorded as follows: 7 (20.59%) patients were grade 1 (partially or moderately satisfied), 22 (64.7%) patients were grade 2 (greatly satisfied) and 5 (14.7%) patients were grade 3 (fully satisfied).

Follow up

All patients were followed up at 2, 6, 12 weeks, and 6 months after the last treatment session. We noticed improvement during the first three follow up visits (2, 6 and 12 weeks) and this improvement was sustained throughout the further 3 months of follow up (i.e. at 6 months follow visit) with no more improvement.

Side-effects

Erythema, bruising, and swelling were noticed in all treated patients at the time of procedure of subsicion. The time needed for these side-effects to resolve was 3–4 days in 32 (94.12%) the patients. This time was extended to 1 week in only two (5.88%) patients. Two (5.88%) patients developed severe facial swelling and one (2.94%) patient developed erythema on the lower eyelid which were resolved within 3 days. Postoperative mild pain was recorded by all patients and resolved within 3–4 days. All patients developed firm bumps under the treated scar areas. At 2 weeks after treatment, all side-effects disappeared apart from the firm bumps. At 6 weeks after treatment, 28 (82.35%) patients were having firm bumps and at 12 weeks after treatment, no patient had any bumps. The patients were also seen after

Table 2 Grades of patients with acne scars before treatment, 2, 6, 12 weeks, and 6 months after treatments

Grade	No. of patients before treatment (%)	No. of patients at 2 weeks after treatment (%)	No. of patients at 6 weeks after treatment (%)	No. of patients at 12 weeks after treatment (%)	No. of patients at 6 months after treatment (%)
Mild	0 (0%)	1 (2.94%)	13 (38.23%)	18 (52.94%)	18 (52.94%)
Moderate	26 (76.48%)	28 (82.35%)	20 (58.82%)	15 (44.11%)	15 (44.11%)
Severe	8 (23.52%)	5 (14.7%)	1 (2.94%)	1 (2.94%)	1 (2.94%)
Total	34 (100%)	34 (100%)	34 (100%)	34 (100%)	34 (100%)

$$\chi^2 = 51.6.$$

$$df = 8.$$

$$P \text{ value} = 0.0000001.$$

Table 3 The scores of patients before treatment, 2, 6, 12 weeks, and 6 months after treatment with their means \pm SD

Score before treatment	Score 2 weeks after treatment	Score 6 weeks after treatment	Score 12 weeks after treatment	Score 6 months after treatment
13.264 \pm 1.675	12.411 \pm 1.86	9.852 \pm 2.664	9.588 \pm 2.688	9.47 \pm 2.71

FT = 19.38.

P-value Statistically highly significant ($P = 0.0000001$).

Table 4 Visual analogue scales (VAS) before and after treatment with their means \pm SD

No. of sessions	VAS before subsicion	VAS after subsicion
1.2 \pm 0.516	5.828 \pm 1.807	3.088 \pm 1.725

FT = 41.21.

P-value statistically highly significant ($P = 0.0000001$).

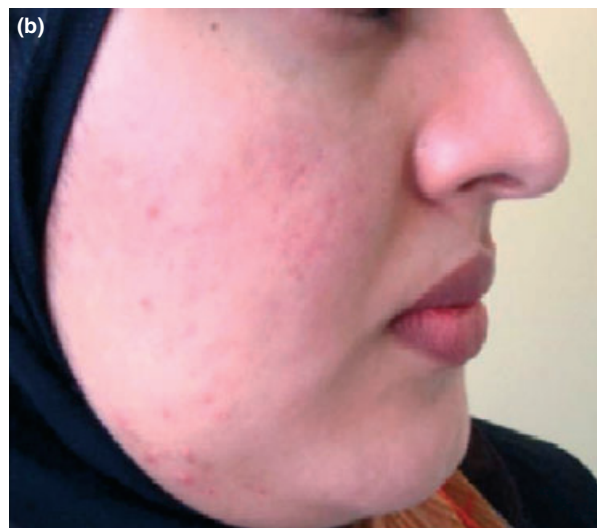
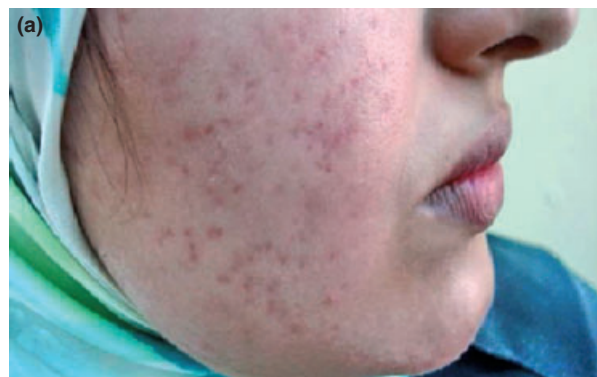
Figure 2 A patient with acne scars before (a) and after (b) subsicion.

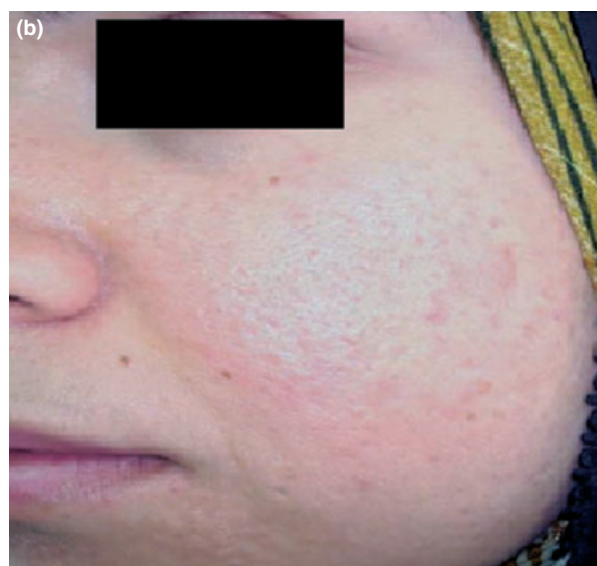
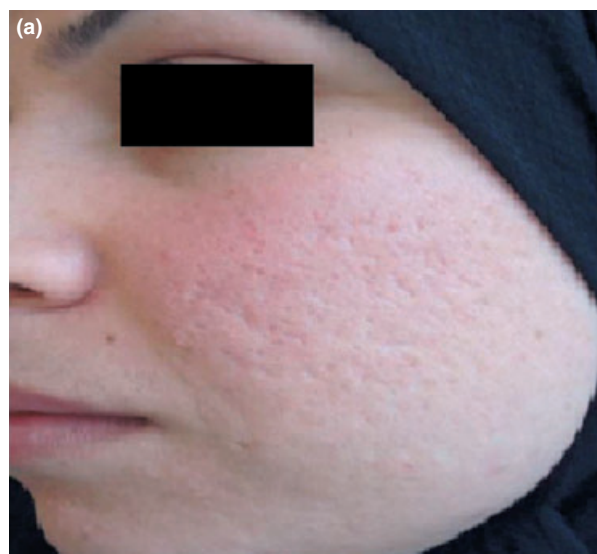

Figure 3 A patient with acne scars before (a) and after (b) subsicion.

6 months and none of them was complaining of any side-effect.

Discussion

Many treatment modalities have been proposed for acne scars with inconstant outcome. Subcision is a simple procedure in patients with rolling depressed acne scars. It was first invented by Orentreich and Orentreich¹⁷ for treatment of depressed acne scars and wrinkles. Subcision® included the use of inexpensive needle to treat any area of the face. It makes the rolling acne scars less noticeable. It appears to be ineffective for revision of deep scars or those with abrupt vertical wall like boxcar or icepick scars.

There are few published data in the literature that shed light on the effectiveness and safety of this procedure in treatment of acne scars.^{16–20} To the best of our knowledge this is the first study regarding subcision performed in Iraq. Alam *et al.*¹⁶ evaluated the efficacy of subcision for the treatment of rolling acne scars in 40 patients. He demonstrated approximately 50% improvement of depressed scars as seen in this study. His evaluation depended on investigator's rating and patient's satisfaction, but that study lacked an objective scoring system and statistical analysis in contrast to this study where Sharquie's scoring system for grading scarring acne vulgaris was used. Balighi *et al.*¹⁸ also used subcision for treatment of depressed acne scars in 22 patients. He did not use an objective scoring system. Goodman¹⁹ reported two cases with facial scars improved by subcision using a 19 gauge needle. Fulchiero *et al.*²⁰ reported a case with acne scars improved by subcision, followed by further improvement after nonablative resurfacing with 1320 nm ND: YAG laser. These studies are underpowered regarding patients number compared with our series. Also, photographic assessment using VAS showed that subcision was an effective method for treating acne scars (P value <0.000001). It gave us another objective evidence of assessment.

The exact mechanism of improvement of depressed acne scars observed after subcision is not very clear. Two mechanisms were proposed by Orentreich and Orentreich.¹⁷ The first mechanism is cutting the fibrous tissue tethering the skin to the underlying subcutaneous tissue. The second mechanism is the creation of controlled trauma to promote new connective tissue formation under the defect in the course of wound healing. After subcision, wound healing begins with a vascular response, then subsequent phases of inflammation, granulation tissue formation, and fibroplasias happen. Surface reepithelialization is essentially absent,

as subcision only minimally involves the epidermis. Ground substance is produced, and collagen synthesis (peaking at 6–7 days) continues for 2–4 weeks. Finally, long-term collagen remodeling occurs.¹⁷ This may explain the appearance of a localized hypertrophic reaction (firm bumps) following subcision (see below).¹⁶

An 18-gauge needle was used to undermine the area under each acne scar with forward, backward, and fan-like motion. Previous studies used a tribeveled needle for subcision.^{16,17} This study showed that an ordinary 18-gauge needle is also effective with no difference in the outcome. The use of needle holder for holding of the treatment needle was very useful for better control of the movement and direction of the needle during the treatment session. Most other studies used hands or sometimes syringe during the subcision session.

In the present study, the most obvious improvement in most of the patients was recorded after 6 weeks of the last treatment session (Table 2). Few patients improved from moderate to mild grade after 12 weeks. No further improvement in the acne scars was recorded after that. This is an important fact and the patients should wait this period to observe the maximum effect. Absence of any further improvement after 12 weeks indicates that this is the best time to retreat with subcision if needed.

Regarding patients' satisfaction, all patients were satisfied with varying degrees compared with 90% of patients were satisfied that subcision improved their acne scars in the study of Alam *et al.*¹⁶ This satisfaction reflected the dramatic effect of the improvement of their acne scars on their psyche which was severely affected before treatment. The paucity and the transient and mild features of the side-effects may further improve the patient satisfaction.

Most of the patients (82.35%) improved after only one session of subcision, which is consistent with the previous published studies.^{16,18} Only four (11.76%) patients required two sessions and two (5.88%) patients required three sessions of subcision to get improvement. Additional sessions were needed to treat either non-treated or partially treated scars. This means that one session is sufficient for the majority of cases and those with extensive acne scars may need multiple sessions.

There was no side-effect within few weeks after subcision. They were no more than mild local edema, erythema, bruising, and postoperative pain resolved within 3–4 days. Firm bumps at the treatment sites developed as small indurations in all patients similar to the previous published studies.^{16–18} These bumps were palpable rather than visible and may be responsible for some of the improvement of the depressed scars. They didn't cause any cosmetic disfigurement to the patient.

These indurations resolved by 12 weeks of the procedure in all patients without any regression in the improvement achieved. Patients should be reassured and told that these indurated areas will remit with time without any complication.

Other methods for treatment of acne scars had been used In Iraq, Al-Waiz and Al-Sharqi²¹ used medium depth chemical peel (combination of Jessner's solution followed by the application of 35% trichloroacetic acid [TCA]) in the treatment of acne scars in dark skinned individuals and reported moderate improvement, but with transient postinflammatory hyperpigmentation in 73.4% of the patients which resolved within 3 months. Hyperpigmentation was not encountered after subsision in the present study.

Lasers had been used in the treatment of acne scars. Maluki²² used pulsed CO₂ laser resurfacing and achieved good results. Although laser is easy to operate and achieve precise depth, it is expensive and available only in few centers in Iraq at this time and may be associated with potential side-effects such as hypo or hyperpigmentation and scarring which are not encountered with subsision. Comparing subsision to the other modalities of treatment of acne scars indicates that it is a simple procedure and does not need much preparation. Only local anesthesia is required. It is not complicated by any hypo or hyperpigmentation noticed in other modalities such as chemical peel, dermabrasion, and lasers.⁷ Also, there is no potential for scarring following subsision in contrast to dermabrasion and lasers.⁷ None of our patients developed postoperative infection which is a possible complication of dermabrasion. No sun avoidance is required as that is needed following chemical peel, dermabrasion, and lasers. All that needed is 1–2 days work leave.

Subsision appear to be simple, safe, well tolerated surgical tool to improve selected people with acne scars. It is useful mainly for rolling depressed scars and pf no much effect in those with icepick or boxacar scars. It can be part of multiple types of treatments used for patients with acne scars. It can lead to overall improvement in those unwilling to undergo other types of sophisticated treatments like laser, dermabrasion or dermal fillers.

References

- Rivera AE. Acne scarring: a review of current treatment modalities. *J Am Acad Dermatol* 2008; **59**: 659–76.
- Cunliffe EJ, Simpson NB. Disorders of sebaceous glands. In: Rook A, Wilkinson DS, Elbing FJE eds. *Rook's Textbook of Dermatology*, vol. 3, 7th edn. Oxford: Blackwell Scientific Publications, 2004: pp. 43.1–43.72.
- Jacob CI, Dover JS, Kaminer MS. Acne scarring: a classification system and review of treatment options. *J Am Acad Dermatol* 2001; **45**: 109–17.
- Sharquie K, Al-Hamdi K, Noaimi AA, Al-Battat R. Scarring & nonscarring facial acne vulgaris & frequency of associated skin disease. *Iraq Postgrad Med J* 2009; **8**: 332–8.
- Goodman G. Post acne scarring: a review. *J Cosmet Laser Ther* 2003; **5**: 77–95.
- Goodman GJ, Baron JA. The management of postacne scarring. *Dermatol Surg* 2007; **33**: 1175–88.
- Alster TS, West TB. Treatment of acne scars: a review. *Ann Plast Surg* 1997; **39**: 418–32.
- Lee JB, Chung WG, Kwahck H, Lee KH. Focal treatment of acne scars with trichloroacetic acid: chemical reconstruction of skin scars method. *Dermatol Surg* 2002; **28**: 1017–21.
- Savardekar P. Microdermabrasion. *Indian J Dermatol Venereol Leprol* 2007; **73**: 277–9.
- Orentreich D, Orentreich N. Acne scar revision update. *Dermatol Clin* 1987; **5**: 359–68.
- Bellew SG, Weiss MA, Weiss RA. Comparison of intense pulsed light to 595-nm long-pulsed pulsed dye laser for treatment of hypertrophic surgical scars: a pilot study. *J Drugs Dermatol* 2005; **4**: 448–52.
- Walia S, Alster TS. Prolonged clinical and histological effects from CO₂ laser resurfacing of atrophic acne scars. *Dermatol Surg* 1999; **25**: 926–30.
- Woo SH, Park JH, Kye YC. Resurfacing of different types of facial acne scar with short-pulsed, variable-pulsed, and dualmode Er:YAG laser. *Dermatol Surg* 2004; **30**: 488–93.
- Alster TS, Lupton JR. Nonablative cutaneous remodeling using radiofrequency devices. *Clin Dermatol* 2007; **25**: 487–91.
- Bogle AB, Arndt KA, Dover JS. Plasma skin regeneration technology. *J Drugs Dermatol* 2007; **6**: 1110–2.
- Alam M, Omura N, Omura M, Kaminer MS. Subsision for acne scarring technique and outcome in 40 patients. *Dermatol Surg* 2005; **31**: 310–7.
- Orentreich DS, Orenreich N. Subcutaneous incisionless (Subsision) surgery for the correction of depressed scars and wrinkles. *Dermatol Surg* 1995; **21**: 543–9.
- Balighi K, Robati RM, Moslehi H, Robati AM. Subsision in acne scar with and without subdermal implant: clinical trial. *J Eur Acad Dermatol Venereol* 2008; **22**: 707–11.
- Goodman GJ. Therapeutic undermining of scars (Subsision). *Aust J Dermatol* 2001; **42**: 114–7.
- Fulchiero JR, Gregory J, Pamela C *et al*. Subsision and 1320-nm Nd:YAG nonablative laser resurfacing for the treatment of acne scars: a simultaneous split-face single patient trial. *Dermatol Surg* 2004; **30**: : 1356–60.
- Al-Waiz M, Al Sharqi Ali I. Medium depth chemical peels in treatment of acne scars in dark skinned individual. *Dermatol Surg* 2002; **28**: 383–7.
- Maluki AH. Facial resurfacing of atrophic acne scars using high energy pulsed carbon dioxide laser. *J Arab Board Med Specialization* 2003; **5**: 105–8.