

doi: 10.5455/medarh.2015.69.384-386

Med Arh. 2015 Dec; 69(6): 384-386

Received: September 15th 2015 | Accepted: November

15th 2015

© 2015 Mohammadai Nilforoushzadeh, Elahe Lotfi, Elmira Nickkholgh, Bahareh Salehi, Marjan Shokrani

This is an Open Access article distributed under the terms of the Creative Commons Attribution Non-Commercial License (<http://creativecommons.org/licenses/by-nc/4.0/>) which permits unrestricted non-commercial use, distribution, and reproduction in any medium, provided the original work is properly cited.

Can Subcision with the Cannula be an Acceptable Alternative Method in Treatment of Acne Scars?

Mohammadali Nilforoushzadeh¹, Elahe Lotfi², Elmira Nickkholgh³, Bahareh Salehi³, Marjan Shokrani⁴

¹Skin and Stem Cell Research Center, Tehran University of Medical Sciences, Tehran, Iran. Skin Diseases and Leishmaniasis Research Center, Isfahan University of Medical Sciences, Isfahan, Iran

²Skin Diseases and Leishmaniasis Research Center, Isfahan University of Medical Sciences, Isfahan, Iran. Skin and Stem Cell Research Center, Tehran University of Medical Sciences, Tehran, Iran

³Jordan Dermatology and Hair Transplantation Center, Tehran, Iran

⁴Skin and Stem Cell Research Center, Tehran University of Medical Sciences, Tehran, Iran

Corresponding author: Dr. Elahe Lotfi, MD. Tel: +98-2188788707, +98-2188788667, Fax: +98-2188882850, Postal Code: 1518963113. E-mail: El_le_18@yahoo.com

ABSTRACT

Background and objectives: Most people who experience the acne suffer from damage under the surface of their skin which causes saucer-like depressions or pits on their skin. Sometimes the skin loses its underlying support and develops fibrous bands of tissue between the skin and subcutaneous layer, which pull on the epidermis and cause a wavy texture called as rolling scar. Treatment of acne scars is a therapeutic challenge that may require multiple modalities. Subcision is a procedure that has been reported as a beneficial method in the treatment of rolling acne scars. Although Subcision is a valuable method, its efficacy is mild to moderate because of the high recurrence rate and patients dissatisfaction due to some side effects include post procedure inflammation. **Materials and methods:** This pilot study is a clinical trial. The 8 patients suffered from mild to severe rolling acne scars on their face with symmetrical distribution of lesions, underwent Subcision with the Cannula No 18 and 21 and followed-up for 3 months. Outcomes of Subcision procedures were assessed by 3 board certified dermatologists (blind) after 2 session of treatment. The patients' satisfaction was considered to compare with dermatologist's opinions. The degree of improvement and satisfaction of the treatment estimated with these points: poor: 0, fine: 1-3, good: 4-6, and very good: 7-9. The data were finally analyzed with SPSS-18 software. **Results:** Subcision with the Cannula showed good and very good improvement in about 88% of patient with a satisfaction good and very good improvement in all of patients (100%). Assessment of photographic data showed 100% improvement in scar depth, topography and overall appearance of acne scars. The average numbers of lesions before the treatment were 24.8 ± 12.1 and after treatment it was reduced to 12.8 ± 2.1 ($p < 0.05$). **Conclusion:** Subcision with the Cannula appears to be a safe method with high efficacy in the treatment and high satisfaction in patients as we observed an interesting cure rate (more than 50% after 2 sessions). It demonstrates to be a safe procedure because it performed by single perforation in each side instead of multiple perforations that helps to reduce the patients' pain and risk of scars. In other hand Cannula-based Subcision needs considerable fewer sessions of surgery and also less recovery time.

Key words: Acne Scars, Subcision, Cannula, efficacy, Side effects.

1. INTRODUCTION

Acne is a common dermatological disorder causing a great cosmetic disfigurement (1). Because acne scars can have a different appearance and depth, there are various

treatments for them based on the type and severity of tissue damage remains after the healing of first lesion (2, 3, 4). Subcision is one of the proposed treatments that have been reported to be beneficial approach

especially in post acne deep rolling scars. It is a Known therapeutic method in which we can use different tools. Although it seems that, there had not been a huge difference in the result of using various tools, such as the effectiveness, side effects, duration of procedure and so on, but numerous studies have been conducted in this area to find the best method that in addition to better results can provide a patient and physician satisfaction.

In a study in 1995 as pioneers (5) it was reported that Subcision with tri-beveled hypodermic needles can be a potential procedure in treatment of skin depressions which can cause the deep rolling scars after acne lesions. Also, some other studies demonstrated that Subcision with a wire scalpel can be an excellent candidate to treat depressed scars, wrinkles, and folds which develop as a result of acne (6, 7, 8). Although Subcision has very minimal side effects, depression recurrence is very common issue particularly 2 weeks after first treatment. In other hand the procedure can cause bruising and soreness and sometimes it can forms hematoma. Moreover the risk of infection or prolonged pain is considerable as well. As an alternative to the wire scalpel method to assess the efficacy of Subcision with Cannula, we design herein a modified Subcision technique using an 18 and 21 gauge metal type spinal needle Cannula (Hakko Co., Chikuma, Japan). As we know, this tool is cheaper than other tools used before and its preparation is easier. The main goal of preparation of this pilot study was to evaluate the effectiveness of this method, duration of treatment, side effects, patient satisfaction and physician satisfaction after using this tool as an alternative to needle. We are looking for a tool with high performance, high efficiency, low recurrence rate, and minimal side effects that are cheap and accessible for patients and convenient for doctors.

2. MATERIALS AND METHODS

This is a pilot study. We chose 8 patients who suffered from rolling scars caused by acne. As we know patients' awareness of the treatment process is very effective in their expectation of the outcome of treatment. So all the stages of treatment, treatment methods and tools that we used, the effectiveness of this method according to the history, and the possible complications explained to patients. The mean age of the participants was 31.2 years and all of them were female. The area to be Subcised (about 10 mm wide) was outlined while the patients were sitting in a fixed and comfortable position. All patients were subjected to 1% lidocaine solution as a local anesthetic and an anti-arrhythmic drug containing 1:100,000 epinephrine. The 18-gauge spinal needle Cannula was used for Subcision of scars. The Cannula was inserted into the superficial dermis and passed through the sub-dermal plane parallel to the skin surface. Rapid repetitive back and forth motion of the needle was performed to scrape the underside of the dermis and disconnect scar sub-surfaces such as the base, walls, borders and shoulders. Then, side-to-side needle motion called as fanning motion was also introduced to completely release fibrous tissues.

After the final step, ice compression was applied to the site of treatment for 20 minutes. Photos of patients were taken using Vision-face before the start of treatment and after the final step of treatment. Outcomes of Subcision procedures were assessed by 3 board certified dermatologists (blind). Patients' satisfaction was estimated at the end of the treatment process. The degree of the improvement was rated as follow: poor: 0, fine: 1-3, good: 4-6, and very good: 7-9. The data on target were analyzed using the SPSS-18 software.

3. RESULTS

Out of total amount in our sample, 8 patients (female) were enrolled in the study and underwent Subcision with the Cannula. After analyzing the findings of evaluation of photos (took before and after the treatment) by specialists, the results showed good and very good improvement in about 88% of patient. The results of patient satisfaction showed good and very good improvement in all of the participations (100%). Photographic data showed a significant improvement in topography, level of scar depth, and overall appearance of the acne scars in all 8 patients (Figure 1, 2, 3). Patients with mild active acne experienced a reduction in formation of scar after active phase of disease during the treatment and follow-up interval. The average numbers of lesions before the treatment were 24.8 ± 12.1 and after treatment it was reduced to 12.8 ± 2.1 ($p < 0.05$). Transient post procedure mild swelling and inflammations were detected among our patients that were cleared completely after 2 weeks

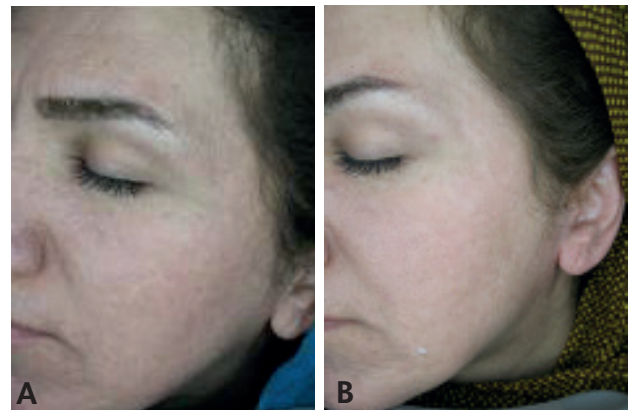


Figure 1. Case 1 (female, 42 years). A: before the treatment. B: after the treatment.

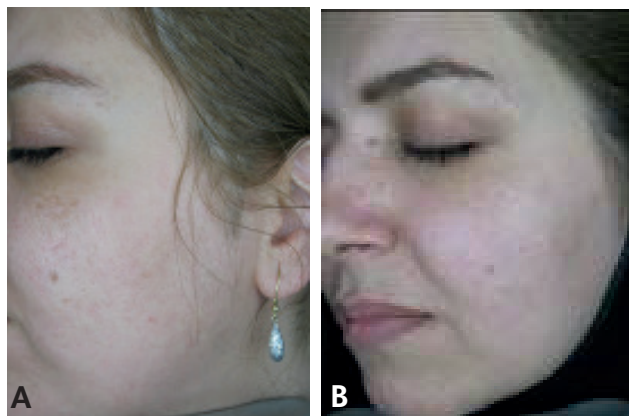


Figure 2. Case 2 (female, 36 years). A: before the treatment. B: after the treatment.

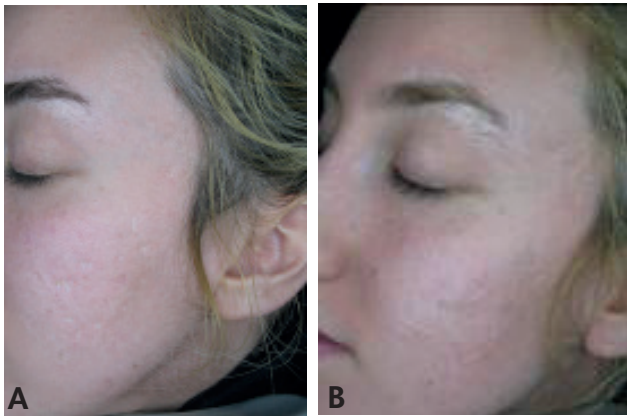


Figure 3. Case 3 (female, 30 years). A: before the treatment. B: after the treatment.

of therapy. Severe swelling, bruising and also skin infection weren't observed in any cases of under examined patients. There was no evidence of hyper pigmentation or hypertrophic scar. The participations were followed up for 3 months and they were not showed any side effect or recurrence during the course of the investigation.

4. DISCUSSION

All surgical techniques are developed and modified continuously with the purpose of achieving the best outcomes through easier, comfortable, and practical ways to get the best final results with fast recovery and the least complications. Prominent skin scar depression can be noticeably improved using a wide range of treatment modalities. To obtain optimal results, the treatment design should be planned according to the patient's situations such as age, aesthetic needs, anticipated downtime, sensitivity, and so on (8). Subcision is a valuable surgical technique that can be applied to lessen depressed scars, wrinkles, striae, cellulite, boxcar and serious pitted scars (8). This technique applied generally to control depressed scars. As described by S. Orentreich and N. Orentreich in 1995, Subcision aims to sever the fibrous components beneath the scar, at the sub-dermal stage. It helps to lift up the scar and produce the forming of connective tissues through usual physiological healing (5). It was done by using a Nokor or hypodermic needle (needle gauge depends on the size of the scar). Over time, many modifications to this surgical technique have been made by various surgeons in order to make it simpler and more effective. One modification made by N. Khunger and M. Khunger was bending the needle at a 90-degree angle artery forceps to prevent the penetration of the skin or causing damage to the dermis (9). Another modification made by Al Ghamdi was using a needle holder for the Nokor needle to maintain its horizontal orientation without the need for withdrawal from the entry point to visualize the orientation and redirection of the needle (10). In this study, we assessed all aspects of the use of another special device (Cannula) in Subcision of acne-induced scars that appear to be safe and efficient. We focused on the treatment of acne scars by means of Subcision procedure with the Cannula to break up fibrous bands that cause rolling scars. We observed an interesting cure rate

data (more than 50% after 2 weeks) relative to other reported ones (around 30-40%). Hypertrophic scar and hyper-pigmentation, Ecchymosis, swelling and redness are common side effects among Subcision with Needle that are reported in 50% of patients (even increase to 70-80% of patients), but Subcision with the Cannula appears to be a safe method with high efficacy in treatment and high satisfaction in patients (8-11). Another superiority of our new designed method is that Subcision with Cannula have been performed by single perforation in each side instead of multiple perforations that helps to reduce the patients' pain and risk of scars during and after the procedure. Furthermore, Cannula-based Subcision relative to needle-based Subcision needs considerable fewer sessions of surgery and also it requires less recovery time. In general all these advantageous points come to enhancement of patient satisfaction. However, further controlled trials should be conducted to assess the efficacy and side effects of Cannula in comparison with needle and other techniques.

5. CONCLUSION

Subcision with Cannula can be replaced instead of other tools that are used in the treatment of the scars caused by acne. This treatment method is less invasive, with fewer complications and more satisfaction of patients. In addition therapeutic techniques using these tools are easier for doctors and they are associated with more satisfaction of them and finally the treatment will done in less time.

CONFLICT OF INTEREST: NONE DECLARED.

REFERENCES

- Garg VK SS, Sarkar R. Glycolic acid peels versus salicylic-mandelic acid peels in active acne vulgaris and post-acne scarring and hyper pigmentation: A comparative study. *Dermatol Surg.* 2009; 35: 59-65.
- Koo JY SL. Psychologic aspects of acne. *Pediatr Dermatol.* 1991; 8: 185-188.
- Nilforoushazadeh MA SA, Haftbaradaran E, Moradi Sh. Clindamycin lotion alone versus combination lotion of clindamycin phosphate plus tretinoin versus combination lotion of clindamycin phosphate plus salicylic acid in the topical treatment of mild to moderate acne vulgaris. *Indian J Dermatol Venereal Leprol.* 2009; 75: 279-282.
- Nilforoushazadeh MA FG, Jafari F, Haftbaradaran E, Hoseini M, Mazaheri N. Comparison of Fractional Carbon Dioxide Laser Alone and in Combination with Subcision in Improving Atrophic Acne Scars. *Journal of Isfahan Medical School.* 2013;31:226.
- Orentreich DS ON. Subcutaneous incisionless (Subcision) surgery for the correction of depressed scars and wrinkles. *Dermatologic Surgery.* 1995; 21: 543-549.
- Aalami Harandi SBK, Lajevardi V, Akbari E. Subcision-suction method: a new successful combination therapy in treatment of atrophic acne scars and other depressed scars. *Journal of the European Academy of Dermatology and Venereology.* 2011; 25: 92-99.
- Alam M ON, Kaminer MS. Subcision for acne scarring: Technique and outcomes in 40 patients. *Dermatol Surg.* 2005; 31: 310-317.
- Jordan R CC, Burls A. Laser resurfacing of the skin for the improvement of facial acne scarring: a systematic review of the evidence. *Br J Dermatol.* 2000; 23: 412: 3.
- KM AG. A better way to hold a nokor needle during Subcision. *Dermatol Surg.* 2008; 34: 378-379.
- Khunger NKM. Subcision for depressed facial scars made easy using a simple modification. *Dermatologic Surgery.* 2011; 37: 514-517.