

# BOTULINUM TOXIN (BOTOX) TO ENHANCE FACIAL MACROESTHETICS: A LITERATURE REVIEW

Sarosh F. Dastoor, DMD; Carl E. Misch, DDS, MDS; Hom-Lay Wang, DDS, MSD

Dental implants have emerged as a predictable treatment option for partial edentulism. Their ability to preserve bone and soft tissue yields highly esthetic results in the long term. Increasingly, patients are demanding not only enhancements to their dental (micro) esthetics but also to their overall facial (macro) esthetics. Dynamic wrinkles (caused by hyperfunctional muscles) in the perioral, glabellar, and forehead regions can cause a patient's expressions to be misinterpreted as angry, anxious, fearful, or fatigued. An emerging treatment option to address these issues is the use of a paralyzing material such as botulinum toxin A (Botox) to decrease the appearance of the wrinkles, which yields a more esthetic and youthful facial appearance. Botox is a deadly poison that is produced by the bacterium *Clostridium botulinum* and causes muscle paralysis by inhibiting acetylcholine release at the neuromuscular junction. When used in areas of hyperfunctional muscles, a transient partial paralysis occurs that diminishes the appearances of wrinkles. Therefore, wrinkles not attributable to hyperfunctional muscles (eg, wrinkles caused by aging, gravity, photodamage, trauma, and scarring) will not be amenable to treatment with the toxin. As a result, proper case selection is essential. A thorough understanding of the indications, techniques, dosages, and complications and their management is imperative to achieve a satisfactory result. This article will review the pathogenesis of facial wrinkles as well as the history, techniques, clinical controversies, and other important considerations for successful treatment of facial wrinkles with Botox.

**Key Words:** botulinum toxin, botox, soft tissue augmentation, macroesthetics, wrinkles, rhytides

## INTRODUCTION

Dental implants have emerged as a predictable long-term option for treating partial edentulism.<sup>1-5</sup> In addition to restoring optimal function and phonetics, dental implants preserve the hard and soft tissue, yielding proper emergence profiles. These advantages enhance the microesthetics (anything inside the oral cavity) of the final

case. Another aspect that may be considered during successful implant therapy is enhancing the overall macroesthetics (anything outside the oral cavity) of the patient's face. Dynamic wrinkles, which are attributable to hyperfunctional muscles in the perioral, glabellar, and forehead regions can cause a patient's expression to be misinterpreted as angry, anxious, fearful, or fatigued. Often, patients request adjunctive treatments that address these concerns, ultimately leading to a more overall pleasing appearance. Coupled with enhancing the intraoral esthetics via dental implants, treating dynamic wrinkles with botulinum toxin can provide patients with a highly esthetic final result. This article will discuss the history, materials, general techniques, and other important considerations for successful treatment with botulinum toxin.

---

*Sarosh F. Dastoor, DMD, is a resident, Carl E. Misch, DDS, MDS, is a professor, and Hom-Lay Wang, DDS, MSD, is a professor and the director of graduate periodontics, Department of Periodontics and Oral Medicine, School of Dentistry, University of Michigan, Ann Arbor. Address correspondence to Dr Wang at Department of Periodontics and Oral Medicine, University of Michigan School of Dentistry, 1011 N University Ave, Ann Arbor, MI 48109-1078 (e-mail: homlay@umich.edu).*

### PATHOGENESIS OF FACIAL WRINKLES

A rhytide, or wrinkle, may be divided into dynamic and static conditions. Dynamic wrinkles occur during the contraction of muscles and are most prominent in the forehead and periorbital regions of the face. They are the product of the repeated and habitual contraction of the underlying muscles of facial expression. When the contraction of a facial muscle is accompanied by a lack of shortening of the skin, a wrinkle is produced. The amount of facial change is related to the depth of the depression within the mucosa or submucosa of the tissue. The terminology for the degree of relative change to the skin includes folds, wrinkles, and lines (Figure). A fold develops when the depression extends through the dermis and approximates the subcutaneous tissues. A wrinkle proceeds through the epidermis and extends to the dermis of the skin. A line remains completely within the epidermis and does not approach the dermis of the skin.<sup>6</sup> Factors that can affect the depth of a wrinkle include skin texture, amount of subcutaneous fat, water content of the skin, distribution and ratio of collagen and elastic fibers, biochemical changes in the connective tissue, and interstitial spaces.<sup>7,8</sup>

Static wrinkles occur as a result of aging, photodamage, trauma, or scarring. Tissue laxity occurs as a function of age, especially in the nasolabial fold areas. The effect of gravity can deepen facial wrinkles. Additionally, atrophy of the skin occurs: there is loss

of dermal papillae, reduction in the number of Langerhans cells, melanocytes, and the total amount of dermal connective tissue (which is composed of glycosaminoglycans and proteoglycans) decreases. There is a clinically significant loss of collagen fibers to the point that the elastin to collagen ratio may change in favor of elastin. Another cause of wrinkles is damage to the skin. Harmful doses of ultraviolet radiation have been recorded in normal sunlight, most fluorescent light, and in sun-tanning booths.<sup>9</sup> Ultraviolet radiation, via generation of superoxide radicals, causes actinic skin damage, which manifests as a decrease in mature type I collagen and an increase in immature type III collagen. Other causes of static facial wrinkles include trauma, scarring, and disease processes that alter the quality of collagen in the dermis, which can present as excessive skin laxity or premature aging. Such conditions that enhance facial wrinkles include Ehlers-Danlos syndrome, progeria, and pseudoxanthoma elasticum.

### CASE SELECTION

Wrinkles attributable to photodamage, age, trauma, and scarring (static wrinkles) are not amenable to treatment with botulinum toxin as they are not caused by hyperfunctional muscles. They are present even when the skin is relaxed. Such wrinkles are more appropriately treated with dermal fillers such as

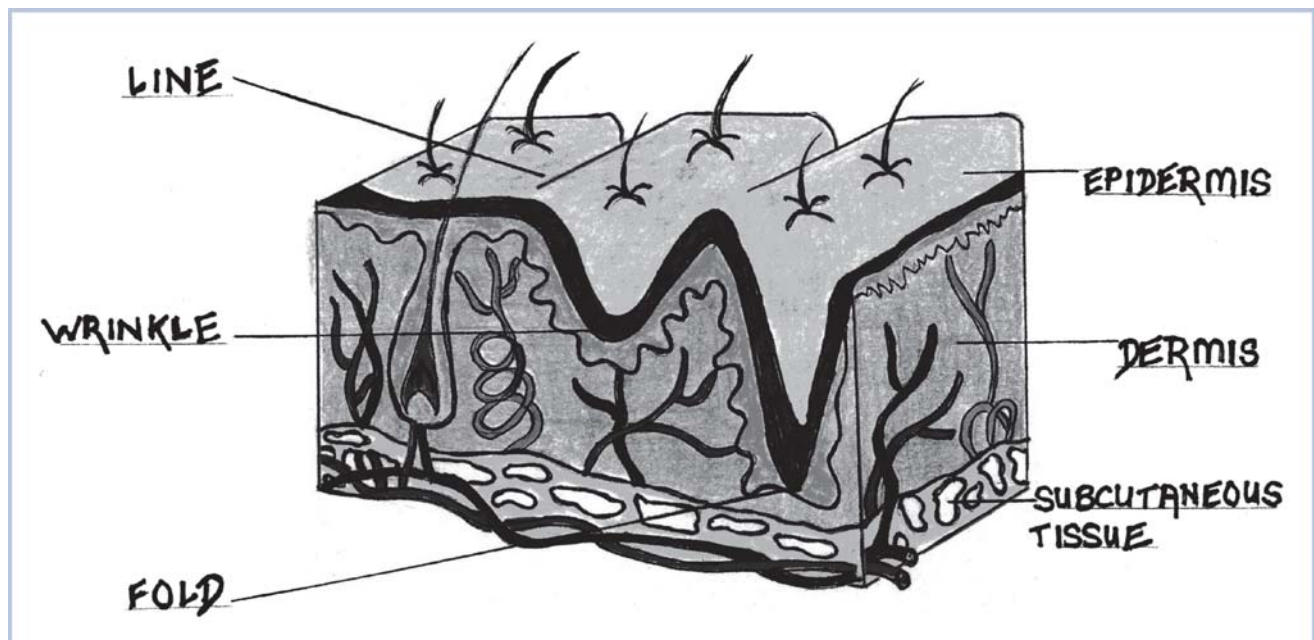


FIGURE 1. Cross section of human skin demonstrating the differences between a line, wrinkle, and fold.

collagen, hyaluronic acid, subcutaneous fat, or various nonresorbable materials.<sup>10-18</sup>

Wrinkles attributable to hyperfunctional muscles (dynamic wrinkles) are best treated with a paralyzing drug such as botulinum toxin.<sup>19</sup> Botulinum toxin is a deadly toxin produced by the *Clostridium botulinum* bacterium. Clinical applications include blepharospasm, strabismus, and hemispacial spasm. New clinical uses in the fields of cosmetic dermatology include the management of hyperfunctional facial lines, most commonly in the regions of the glabella, periorbital crow's feet, and forehead lines. Various studies have outlined certain characteristics of patients successfully treated with the toxin. The ideal patient should have thin skin, fine wrinkles, lines that are exacerbated by muscle contraction, and hyperfunctional lines that can be spread out with the fingers.<sup>20,21</sup>

Preoperative communication is of vital importance. Most patients simply desire a return to their youthful image and do not desire complete dissolution of all lines. Every attempt should be made to fulfill the patient's desires and not create a result that is only esthetically pleasing to the dentist.

#### BOTULINUM TOXIN OVERVIEW

Botulinum toxin is a deadly poison produced by a gram-positive anaerobic bacterium called *C botulinum*. The bacteria produces 7 antigenically distinct toxins that are lettered A through G. Toxin A, however, has been the most extensively studied. The clinical syndrome of botulism occurs after ingestion of contaminated food, from colonization of the infant gastrointestinal tract, or from wound infection.<sup>22</sup> When foods tainted with the toxin are ingested, the toxin spreads to peripheral cholinergic nerve endings, blocking acetylcholine release. This results in a bilaterally symmetric descending neuromuscular illness. The incubation period after ingestion is 18 to 36 hours. In human beings, botulism is mainly caused by types A, B, E, and rarely F, whereas in animals it is caused by types C and D. Outbreaks in the United States sometimes occur after ingestion of home-canned foods, meat products, and preserved fish. The toxin is heat labile and denatured by cooking.

Botulinum toxin is synthesized as a single chain (150 kd) and subsequently cleaved into a di-chain molecule with a disulfide bridge. The light chain acts as a zinc endopeptidase with proteolytic activity located at the N-terminal end. The heavy chain provides cholinergic specificity and binding of the toxin to presynaptic receptors. This promotes translocation of the toxin across the endosomal membrane.

#### HISTORY

The idea for a possible therapeutic use for botulinum toxin was first developed by the German physician and poet Justinus Kerner (1786-1862). He deduced that the toxin acted by interrupting signal transmission within the peripheral sympathetic nervous system, leaving sensory transmission intact. He called the toxin a "sausage poison," because it was observed that illness followed ingestion of spoiled sausage. In 1870, John Muller, another German physician, coined the name "botulism" (from the Latin root *botulus*, which means "sausage"). Subsequent investigators were successful in isolating and culturing the bacterium.

In 1949, Burgen<sup>23</sup> was the first to discover that the toxin was able to block neuromuscular transmission. Scott and colleagues<sup>24,25</sup> proved this fact by experimentally administering the type A strain in monkeys. This strain was approved by the US Food and Drug Administration (FDA) in 1989 under the trade name Botox (Allergan, Inc, Irvine, Calif) for treating strabismus (commonly known as "lazy eye"), blepharospasm (inability to move the eye in certain ways), and hemifacial spasm in patients younger than 12 years old. In 2000, Botox was approved for use in treating cervical dystonia (wry neck) and 2 years later for the temporary improvement of moderate to severe frown lines between the eyebrows (glabellar lines). Since then, Botox has been evaluated off-label for the treatment of spasticity and muscle pain disorders.<sup>26,27</sup> Serotype B has been FDA approved for treating cervical dystonia, and serotype F is under investigation in patients who are resistant to serotypes A and B.<sup>28</sup>

#### MECHANISM OF ACTION

The botulinum toxin causes muscle paralysis by inhibiting acetylcholine release at the neuromuscular junction via 3 steps. First, the toxin binds to the nerve. Then, it is internalized into the nerve. Finally, the toxin is cleaved by internal proteolytic enzymes, and the degradation by-products interfere with the normal process of vesicle fusion to the plasma membrane. This results in the inhibition of the exocytosis of acetylcholine, causing a neuromuscular blocking effect. Although large doses can result in complete paralysis, therapeutic doses allow partial activity, thereby decreasing the visual effects of hyperfunctional wrinkles. Patients should be advised that Botox is not used to keep them from expressing themselves, but simply to keep them from making facial grimaces and frowns that have become habits and are unintended.

## PREPARATION

Botox is prepared by laboratory fermentation of *C botulinum*, which lyses and liberates the toxin into the culture. The toxin is then harvested, purified, crystallized with ammonium sulfate, diluted with human serum albumin, lyophilized, bottled in vials, and sealed. Each vial contains 100 U of Botox. One unit is equal to the amount that will kill 50% of a group of 18 to 22 g Swiss Webster mice when injected intraperitoneally. The human lethal dose is estimated to be approximately 3,000 U. Botox dosages used for cosmetic purposes typically are less than 100 U. Optimal pH of the solution is between 4.2 and 6.8, and vials should be stored in a freezer at or below  $-5^{\circ}\text{C}$ .

Preparations should be reconstituted with 1 to 5 mL of saline without preservatives just before use. Because Botox is easily denatured via bubbling or agitation, the diluent should be gently injected onto the inside of the wall of the vial. The reconstituted solution should be refrigerated at 2 to  $8^{\circ}\text{C}$  and used within 4 hours. A multicenter trial, however, demonstrated that Botox could be used for up to 6 weeks after reconstitution without losing effectiveness.<sup>29</sup> Standardization efforts are underway to determine the minimum dosage needed to cause paralysis.<sup>30,31</sup> Botulinum toxin B is marketed under the trade name Myobloc (Elan Pharmaceuticals, San Francisco, Calif). Its relative potency to Botox is 50 to 125 U of Myobloc to 1 U of Botox. This product does not require reconstitution and is stable for up to 21 months in a refrigerator.

## THERAPEUTIC USES AND CONTRAINDICATIONS OF BOTULINUM TOXIN THERAPY

Botulinum toxin may be used for a variety of disorders ranging from pain management to treatment of tremors and tics, to improvement of the appearance of dynamic facial wrinkles. Table 1 summarizes the therapeutic uses of Botox. Use of Botox has no absolute contraindications. Relative contraindications include patients who are younger than 12 years, are pregnant or lactating, have neuromuscular diseases (eg, myasthenia gravis, Eaton-Lambert syndrome) or motor neuron diseases, have had a previous reaction to the toxin, or have a job that requires them to be demonstrative and have exaggerated facial expressions.

### COSMETIC USES OF BOTULINUM TOXIN: INDICATIONS AND TECHNIQUE

Botulinum toxin has beneficial effects only on wrinkles caused by muscular contractions and is not an

TABLE 1

## Therapeutic uses of botulinum toxin

Disorder	Subtype
Focal dystonia	
<ul style="list-style-type: none"> <li>Involuntary, sustained, or spasmodic patterned muscle activity</li> </ul>	<ul style="list-style-type: none"> <li>Cervical dystonia</li> <li>Blepharospasm</li> <li>Laryngeal dystonia</li> <li>Limb dystonia</li> <li>Oromandibular dystonia</li> <li>Orolingual dystonia</li> <li>Truncal dystonia</li> </ul>
Spasticity	
<ul style="list-style-type: none"> <li>Velocity-dependent increase in muscle tone</li> </ul>	<ul style="list-style-type: none"> <li>Stroke</li> <li>Traumatic brain injury</li> <li>Cerebral palsy</li> <li>Multiple sclerosis</li> <li>Spinal cord injury</li> </ul>
Nondystonic disorders of involuntary muscle activity	
	<ul style="list-style-type: none"> <li>Hemifacial spasm</li> <li>Tremor</li> <li>Tics</li> <li>Myokymia and synkinesis</li> <li>Myoclonus (musculus tensor veli palatine of middle ear, causing tinnitus)</li> <li>Hereditary muscle cramps</li> </ul>
Strabismus and nystagmus	
<ul style="list-style-type: none"> <li>Disorder of conjugate eye movement and rapid involuntary rhythmic eye movement</li> </ul>	
Disorders of localized muscle spasms and pain	
	<ul style="list-style-type: none"> <li>Chronic low back pain</li> <li>Myofascial pain syndrome</li> <li>Temporomandibular joint disorders associated with increased muscle activity</li> <li>Tension headache</li> <li>Migraine headache</li> <li>Cervicogenic headache</li> </ul>
Smooth muscle hyperactive disorders	
	<ul style="list-style-type: none"> <li>Detrusor-sphincter dyssynergia</li> <li>Achalasia cardia</li> <li>Chronic anal fissures</li> </ul>
Cosmetic use	
	<ul style="list-style-type: none"> <li>Hyperkinetic facial lines (glabellar frown lines, crow's feet)</li> <li>Hypertrophic platysma muscle bands</li> </ul>
Sweating disorders	
	<ul style="list-style-type: none"> <li>Axillary and plamar hyperhidrosis</li> <li>Frey syndrome (gustatory sweating of the cheek after parotid surgery)</li> </ul>

appropriate treatment for wrinkles caused by solar exposure or other degenerative processes. Cosmetic indications include its use for the management of hyperfunctional facial lines, most commonly in the regions of the glabella, periorbital crow's feet, and forehead lines. Hyperfunctional frontal, corrugator, or procerus muscles can lead to the appearance of prominent horizontal forehead lines, which can be associated with scowling, aggression, or anger. Hyper-

functional musculus orbicularis oculi can lead to the appearance of "crow's feet" in the periocular region, and these typify age. More experienced clinicians may include treatment of the following: deep wrinkles of the upper lip, nasal scrunching and flaring, deep marionette lines, necklines and platysmal bands, and dimpling of the cheek. Because these further applications can lead to complications that interfere with physiologic functions, they should be approached with caution.

Preoperatively, all makeup should be removed from the patient's face. To compare the effect of treatment, photographs should be taken in both the resting position and in an exaggerated expression (frowning or smiling). The general injection area should then be cleaned with isopropyl alcohol. It is beneficial to use electromyography (EMG) before injections to accurately identify the muscles underlying the wrinkles. The active EMG electrode should be inserted into the muscle. The patient is then asked to maximally contract the muscle in question. The electrode is slowly advanced until a signal of maximum intensity is detected. This indicates maximum muscle contraction and demonstrates the exact location for the injection. EMG is time consuming and expensive; therefore, it is not commonly used in clinical practice. It is however, an excellent teaching tool.

Botox injections are accomplished via a single-point or a skewered method. The needle is inserted parallel to the plane of the muscle, and the injection is performed while the needle is carefully withdrawn. Care should be taken to space injections about 1 to 2 cm apart and to avoid injecting into muscles where paralysis is not desired. Gently pinching the muscle during injection may help reduce pain and ensure superficial placement of the drug. Topical anesthetic or ice may also be used to reduce pain during injection. Pressure with gauze immediately after injection is advisable to prevent bleeding and bruising. Massaging the area after the injection is not recommended, however, to prevent the unwanted diffusion of the toxin into adjacent muscles. Strenuous physical activity should be avoided for 1 day after treatment.

Patients will notice a notable improvement within 1 to 3 days after injection. Maximum improvement is noted at 1 to 2 weeks. The patient should be reexamined at this time. Photographs of the patient making the same expressions as those made preoperatively should be taken for comparison. Repeat treatment at this appointment may be performed; often 2 or 3 treatments are required before the patient is satisfied with the results. The effects of botulinum toxin can last up to 8 to 12 weeks. The beneficial effects may last longer, however, because of a learned

behavior response caused by the chemical paralysis. Repeated treatments with Botox have been shown to cause atrophy of the underlying muscles, usually leading to longer resolution of the wrinkles.<sup>32</sup>

#### DEVELOPMENT OF ANTIBODIES

A small percentage of patients will be resistant to Botox injections and are referred to as "primary nonresponders." Reasons may include inappropriate site of injection, too low of a dose, denatured toxin, or treatment of wrinkles that are not dynamic in origin. Patients should not be diagnosed as primary nonresponders until an experienced clinician has treated them with gradually increasing doses. Patients who initially show some improvements, but later fail to respond completely, are referred to as "secondary nonresponders." This happens because they develop neutralizing antibodies to the toxin.<sup>33</sup> The prevalence of such patients is low; about 5%.<sup>34</sup> Resistance is most likely associated with increased doses and frequency of treatment sessions.<sup>35,36</sup> Repeat doses of 300 U and above have been associated with resistance.<sup>37</sup> Recommended dosages for treating hyperfunctional rhytides, however, are much lower than these; therefore resistance is not a major concern. Again, EMG-guided injections can help to minimize total dosage. The use of other serotypes (F or B) may benefit those who have developed antibody resistance.<sup>28</sup>

#### COMPLICATIONS

Local effects of botulinum toxin are generally transient. Hypersensitivity reactions have not been described. To date, no long-term complications of Botox therapy have been identified.<sup>38</sup> Some short-term, unwanted side effects, however, can affect the patient's everyday life. Several of these complications and their management are described in Table 2.

#### CLINICAL EVALUATION AND CONTROVERSIES REGARDING BOTOX THERAPY

Botox has been shown to be safe and effective in decreasing the appearance of hyperfunctional facial wrinkles versus placebo injections.<sup>39-41</sup> One study showed a distinct advantage of Botox over a xenogenic hyaluronic acid dermal filler called Restalyn (Q-Med, Uppsala, Sweden) in a prospective, controlled clinical trial. Thirty-eight patients were randomized to receive Restalyn, Botox, or a combination of the 2 products to treat moderate to severe glabellar wrinkles. At 32 weeks, clinical and photographic assessments showed

TABLE 2  
Botox therapy complications and management\*

Complication	Cause	Prevention/Management
Pain, bruising		NSAIDs, icepacks
Weakness of adjacent muscles	Diffusion of toxin to adjacent muscles	Avoid postoperative massaging and reapplication of makeup
Ptosis	Injections above the brow are placed too far laterally (past the midpupillary line) or too close to the brow	Phenylephrine apraclonidine (lopidine) eye drops
Delayed eyelid closure, decreased blink response, excessive tearing	Musculus obicularis oris injection is too close to the eyelid	Avoid injection too close to the eyelid
Asymmetry of face	Difference in injection technique or doses between the two sides of the face	Avoid different injection techniques and vastly different doses
Headache		NSAIDs
Antibody development	Excessively large doses	EMG-guided injections can help to minimize total dosage. Use other serotypes (F or B) if antibody resistance has been developed
Necrotizing fasciitis	Immunocompromised patient†	Avoid therapy in immunocompromised patients

\*NSAID indicates nonsteroidal antiinflammatory drug.

†Only one case has been described.

a significantly better response both at rest and on maximum frowning for the patients who received Botox treatment alone or in combination with Restalyn compared with patients who only received Restalyn treatment. The median time for return to preinjection furrow status occurred at 18 weeks in the Restalyn group and 32 weeks for the Botox group.<sup>42</sup>

Many issues regarding the use of Botox are in the process of being resolved. Evidence suggests that higher doses of botulinum toxin type A result in greater efficacy and longer duration in the reduction of wrinkles.<sup>31</sup> This study however, did not have a control group. Another study compared doses of 25 U, 50 U, and 75 U of botulinum toxin in a randomized, double-blind, placebo-controlled clinical trial. The authors found that the moderate dose (50 U) was optimal.<sup>43</sup> Investigations are also underway to determine which strain of the 7 available botulinum toxins is most effective. Compared with type A in a randomized clinical trial, patients who received injections of type B toxin reported slightly more discomfort upon injection. Type B resulted in satisfactory reduction in rhytides, quicker onset of action, and briefer duration of muscle paralysis.<sup>31</sup>

Evidence also suggests that Botox used in combination with other fillers and treatments may be beneficial.<sup>42,44</sup> It has been shown that a combination therapy of Botox and a bovine collagen dermal filler called Zyderm II (Inamed, Santa Barbara, Calif) reduces glabellar furrows more effectively than either therapy used alone.<sup>44</sup> At 3 months, patients who received the combination therapy had significantly greater correction of glabellar furrows. The authors speculated that Botox and the collagen filler could possibly have

a synergistic effect that can be partially attributed to the mechanical effects of muscle contraction in the region. Further trials are needed to determine which areas of the face will most benefit from combination treatments. Finally, it has been shown that adjunctive use of Botox and laser resurfacing appears to be more effective in treating facial wrinkles than laser treatment alone at 6 months.<sup>45,46</sup> One of these trials only evaluated results in 10 women; therefore, studies with larger samples sizes are needed to substantiate this claim.

## CONCLUSION

More often, patients are demanding not only optimal function and esthetics from their dentition but also enhancement of their macroesthetic appearance. Used as an adjunct with dental implant therapy, treatment of hyperfunctional facial wrinkles with Botox can yield a very esthetic final result. Dentists are highly knowledgeable regarding facial anatomy, which gives them a major advantage in case selection and treatment. Therefore, it seems reasonable for them to be at the forefront in providing these services. Understanding limitations of treatment and having the ability to recognize and manage complications are paramount. The ability to use Botox as an adjunctive treatment with dental implant therapy to enhance facial esthetics offers exciting treatment options for dentists and patients in the years to come.

## ACKNOWLEDGMENT

This work was partially supported by the University of Michigan Periodontal Graduate Research Fund.

## REFERENCES

1. Adell R, Eriksson B, Lekholm U, Branemark PI, Jemt T. Long-term follow-up study of osseointegrated implants in the treatment of totally edentulous jaws. *Int J Oral Maxillofac Implants.* 1990;5:347–359.
2. Adell R, Lekholm U, Rockler B, Branemark PI. A 15-year study of osseointegrated implants in the treatment of the edentulous jaw. *Int J Oral Surg.* 1981;10:387–416.
3. Buser D, Weber HP, Bragger U, Balsiger C. Tissue integration of one-stage ITI implants: 3-year results of a longitudinal study with hollow-cylinder and hollow-screw implants. *Int J Oral Maxillofac Implants.* 1991;6:405–412.
4. Nevins M, Langer B. The successful application of osseointegrated implants to the posterior jaw: a long-term retrospective study. *Int J Oral Maxillofac Implants.* 1993;8:428–432.
5. van Steenberghe D, Lekholm U, Bolender C, et al. Applicability of osseointegrated oral implants in the rehabilitation of partial edentulism: a prospective multicenter study on 558 fixtures. *Int J Oral Maxillofac Implants.* 1990;5:272–281.
6. Smith L. Histopathologic characteristics and ultrastructure of aging skin. *Cutis.* 1989;43:414–424.
7. Fenske NA, Lober CW. Structural and functional changes of normal aging skin. *J Am Acad Dermatol.* 1986;15:571–585.
8. Uitto J. Connective tissue biochemistry of the aging dermis. Age-related alterations in collagen and elastin. *Dermatol Clin.* 1986;4:433–446.
9. Sams WM Jr. Sun-induced aging. Clinical and laboratory observations in humans. *Clin Geriatr Med.* 1989;5:223–233.
10. Stegman SJ. Zyderm collagen. Clinical efficacy and tolerance. *Rev Laryngol Otol Rhinol (Bord).* 1987;108:23–26.
11. Cohen SR, Holmes RE. Artecoll: a long-lasting injectable wrinkle filler material. Report of a controlled, randomized, multicenter clinical trial of 251 subjects. *Plast Reconstr Surg.* 2004;114:964–977.
12. Carruthers J, Klein AW, Carruthers A, Glogau RG, Canfield D. Safety and efficacy of nonanimal stabilized hyaluronic acid for improvement of mouth corners. *Dermatol Surg.* 2005;31:276–280.
13. Narins RS, Brandt F, Leyden J, Lorenc ZP, Rubin M, Smith S. A randomized, double-blind, multicenter comparison of the efficacy and tolerability of Restylane versus Zyplast for the correction of nasolabial folds. *Dermatol Surg.* 2003;29:588–595.
14. Duranti F, Salti G, Bovani B, Calandra M, Rosati ML. Injectable hyaluronic acid gel for soft tissue augmentation. A clinical and histological study. *Dermatol Surg.* 1998;24:1317–1325.
15. Lindqvist C, Tveten S, Bondevik BE, Fagrell D. A randomized, evaluator-blind, multicenter comparison of the efficacy and tolerability of Perlane versus Zyplast in the correction of nasolabial folds. *Plast Reconstr Surg.* 2005;115:282–289.
16. Wetmore SJ. Injection of fat for soft tissue augmentation. *Laryngoscope.* 1989;99:50–57.
17. Sommer B, Sattler G. Current concepts of fat graft survival: histology of aspirated adipose tissue and review of the literature. *Dermatol Surg.* 2000;26:1159–1166.
18. Sclafani AP, Romo T, Jacono AA, McCormick S, Cocker R, Parker A. Evaluation of acellular dermal graft in sheet (AlloDerm) and injectable (micronized AlloDerm) forms for soft tissue augmentation. Clinical observations and histological analysis. *Arch Facial Plast Surg.* 2003;2:130–136.
19. Hallett M. One man's poison—clinical applications of botulinum toxin. *N Engl J Med.* 1999;341:118–120.
20. Blitzer A, Binder WJ, Aviv JE, Keen MS, Brin MF. The management of hyperfunctional facial lines with botulinum toxin. A collaborative study of 210 injection sites in 162 patients. *Arch Otolaryngol Head Neck Surg.* 1997;123:389–392.
21. Pribitkin EA, Greco TM, Goode RL, Keane WM. Patient selection in the treatment of glabellar wrinkles with botulinum toxin type A injection. *Arch Otolaryngol Head Neck Surg.* 1997;123:321–326.
22. Cherington M. Botulism: update and review. *Semin Neurol.* 2004;24:155–163.
23. Burgen AS, Dickens F, Zatman LJ. The action of botulinum toxin on the neuro-muscular junction. *J Physiol.* 1949;109:10–24.
24. Scott AB, Rosenbaum A, Collins CC. Pharmacologic weakening of extraocular muscles. *Invest Ophthalmol.* 1973;12:924–927.
25. Scott AB. Botulinum toxin injection of eye muscles to correct strabismus. *Trans Am Ophthalmol Soc.* 1981;79:734–770.
26. Childers MK, Brashear A, Jozefczyk P, et al. Dose-dependent response to intramuscular botulinum toxin type A for upper-limb spasticity in patients after a stroke. *Arch Phys Med Rehabil.* 2004;85:1063–1069.
27. Cheshire WP, Abashian SW, Mann JD. Botulinum toxin in the treatment of myofascial pain syndrome. *Pain.* 1994;59:65–69.
28. Greene PE, Fahn S. Response to botulinum toxin F in seronegative botulinum toxin A—resistant patients. *Mov Disord.* 1996;11:181–184.
29. Hexsel DM, De Almeida AT, Rutowitsch M, et al. Multicenter, double-blind study of the efficacy of injections with botulinum toxin type A reconstituted up to six consecutive weeks before application. *Dermatol Surg.* 2003;29:523–529.
30. Ascher B, Zakine B, Kestemont P, Baspeyras M, Bougara A, Santini J. A multicenter, randomized, double-blind, placebo-controlled study of efficacy and safety of 3 doses of botulinum toxin A in the treatment of glabellar lines. *J Am Acad Dermatol.* 2004;51:223–233.
31. Matarasso SL. Comparison of botulinum toxin types A and B: a bilateral and double-blind randomized evaluation in the treatment of canthal rhytides. *Dermatol Surg.* 2003;29:7–13.
32. Lowe NJ, Lask G, Yamauchi P, Moore D. Bilateral, double-blind, randomized comparison of 3 doses of botulinum toxin type A and placebo in patients with crow's feet. *J Am Acad Dermatol.* 2002;47:834–840.
33. Jankovic J, Schwartz K. Response and immunoresistance to botulinum toxin injections. *Neurology.* 1995;45:1743–1746.
34. Ludlow CL, Hallett M, Rhew K, et al. Therapeutic use of type F botulinum toxin. *N Engl J Med.* 1992;326:349–350.
35. Sankhla C, Jankovic J, Duane D. Variability of the immunologic and clinical response in dystonic patients immunoresistant to botulinum toxin injections. *Mov Disord.* 1998;13:150–154.
36. Kessler KR, Skutta M, Benecke R. Long-term treatment of cervical dystonia with botulinum toxin A: efficacy, safety, and antibody frequency. German Dystonia Study Group. *J Neurol.* 1999;246:265–274.
37. Borodic G, Johnson E, Goodnough M, Schantz E. Botulinum toxin therapy, immunologic resistance, and problems with available materials. *Neurology.* 1996;46:26–29.
38. Naumann M, Jankovic J. Safety of botulinum toxin type A: a systematic review and meta-analysis. *Curr Med Res Opin.* 2004;20:981–990.
39. Keen M, Blitzer A, Aviv J, et al. Botulinum toxin A for hyperkinetic facial lines: results of a double-blind, placebo-controlled study. *Plast Reconstr Surg.* 1994;94:94–99.
40. Carruthers JA, Lowe NJ, Menter MA, et al. A multicenter, double-blind, randomized, placebo-controlled study of the efficacy and safety of botulinum toxin type A in the treatment of glabellar lines. *J Am Acad Dermatol.* 2002;46:840–849.
41. Lowe NJ, Ascher B, Heckmann M, Kumar C, Fraczek S, Eadie N. Double-blind, randomized, placebo-controlled, dose-response

study of the safety and efficacy of botulinum toxin type A in subjects with crow's feet. *Dermatol Surg.* 2005;31:257–262.

42. Carruthers J, Carruthers A. A prospective, randomized, parallel group study analyzing the effect of BTX-A (Botox) and nonanimal sourced hyaluronic acid (NASHA, Restylane) in combination compared with NASHA (Restylane) alone in severe glabellar rhytides in adult female subjects: treatment of severe glabellar rhytides with a hyaluronic acid derivative compared with the derivative and BTX-A. *Dermatol Surg.* 2003;29:802–809.

43. Ascher B, Zakine B, Kestemont P, Baspeyras M, Bougara A, Santini J. A multicenter, randomized, double-blind, placebo-controlled study of efficacy and safety of 3 doses of botulinum

toxin A in the treatment of glabellar lines. *J Am Acad Dermatol.* 2004;51:223–233.

44. Patel MP, Talmor M, Nolan WB. Botox and collagen for glabellar furrows: advantages of combination therapy. *Ann Plast Surg.* 2004;52:442–447.

45. Zimble MS, Holds JB, Kokoska MS, et al. Effect of botulinum toxin pretreatment on laser resurfacing results: a prospective, randomized, blinded trial. *Arch Facial Plast Surg.* 2001;3:165–169.

46. Yamauchi PS, Lask G, Lowe NJ. Botulinum toxin type A gives adjunctive benefit to periorbital laser resurfacing. *J Cosmet Laser Ther.* 2004;6:145–148.